



Efficacy of intravitreal bevacizumab on diabetic macular oedema in an African population

Kyei, S., Asare, F. A., Assan, J. K., Zaabaar, E., Assiamah, F., Obeng, E. O., & Asiedu, K. (2023). Efficacy of intravitreal bevacizumab on diabetic macular oedema in an African population. *IRISH JOURNAL OF MEDICAL SCIENCE*, 192(6), 2777-2783. Advance online publication. <https://doi.org/10.1007/s11845-023-03348-z>

[Link to publication record in Ulster University Research Portal](#)

Published in:
IRISH JOURNAL OF MEDICAL SCIENCE

Publication Status:
Published online: 29/03/2023

DOI:
[10.1007/s11845-023-03348-z](https://doi.org/10.1007/s11845-023-03348-z)

Document Version
Author Accepted version

General rights
Copyright for the publications made accessible via Ulster University's Research Portal is retained by the author(s) and / or other copyright owners and it is a condition of accessing these publications that users recognise and abide by the legal requirements associated with these rights.

Take down policy
The Research Portal is Ulster University's institutional repository that provides access to Ulster's research outputs. Every effort has been made to ensure that content in the Research Portal does not infringe any person's rights, or applicable UK laws. If you discover content in the Research Portal that you believe breaches copyright or violates any law, please contact pure-support@ulster.ac.uk.

Efficacy of intravitreal bevacizumab on diabetic macular oedema in an African population

Samuel Kyei PhD, OD^{1*}, Frederick Afum Asare MSc, OD², John Kwesi Assan OD¹, Ebenezer Zaabaar OD^{1,3}, Frank Assiamah OD⁴, Eric Obour Obeng OD¹, Kofi Asiedu OD⁵

¹Department of Optometry and Vision Science, School of Allied Health Sciences, College of Health and Allied Sciences, University of Cape Coast, Cape Coast, Ghana.

²Centre for Optometry and Vision Science, Biomedical Sciences Research Institute, Ulster University, Coleraine, UK

³Department of Ophthalmology and Visual Sciences, Faculty of Medicine, The Chinese University of Hong Kong, Sha Tin, Hong Kong SAR

⁴Cell Biology and Human Anatomy Department, University of California, Davis, USA.

⁵ School of Optometry and Vision science, Faculty of Medicine and Health, University of New South Wales, Sydney, Australia.

***Correspondence:** Samuel Kyei, Department of Optometry and Vision Science, School of Allied Health Sciences, College of Health and Allied Sciences, University of Cape Coast, Cape Coast, Ghana. Email: skyei@ucc.edu.gh

Conflicts of Interest: None declared.

Acknowledgements

The authors are grateful to the management Dr. Agarwal's Eye Hospital, Ghana.

Funding Source

This research received no specific grant from any funding agency in the public, commercial, or not-for-profit sectors.

Abstract

Purpose: To evaluate the short-term effect of intravitreal bevacizumab (Avastin) injection on visual outcomes of patients with diabetic macular oedema.

Methods: A retrospective cross-sectional study was conducted to evaluate 39 eyes of thirty-nine patients (mean age \pm SD: 61.4 \pm 15.0 years) that received intravitreal bevacizumab injection (1.25 mg in 0.05 ml) as treatment for diabetic macular oedema between January 2014 and July 2019 in Ghana. Data on visual acuity and central macular thickness before treatment and six weeks post-treatment were collected and analysed using paired t-test. Ordinary least squares linear regression analysis was also conducted to determine the relationship between improvement in visual acuity and central macular thickness after treatment and other predictor variables.

Results: The mean \pm SD visual acuity (LogMAR-equivalent of Snellen) of patients with diabetic macular oedema significantly improved from 0.84 \pm 0.58 LogMAR before treatment to 0.69 \pm 0.58 LogMAR at 6 weeks post-treatment (mean difference: 0.15 \pm 0.32 LogMAR; 95% CI: 0.04 to 0.25; $p = 0.01$). Mean macular thickness \pm SD on the other hand, reduced significantly ($p < 0.001$) from 316.54 \pm 75.35 μm before treatment to 275.54 \pm 57.43 μm after treatment. While age and worse pre-treatment visual acuity predicted improvement in visual acuity after treatment, a higher central macular thickness before treatment predicted an improvement in central macular thickness after intravitreal bevacizumab injection.

Conclusion: Treatment with intravitreal bevacizumab injection produces short-term improvement in vision and reduction in central macular thickness in African patients with diabetic macular oedema.

Keywords: Intravitreal bevacizumab, diabetic macular oedema, macular thickness, visual acuity.

Introduction

Diabetic macular oedema is the most common cause of visual impairment in patients with diabetes [1] and the leading cause of blindness among working-aged adults [2,3]. It is characterised by thickening and swelling of the macular secondary to intraretinal accumulation of fluid in the macular area and can develop at any stage in diabetic retinopathy with its prevalence increasing as the severity of diabetic retinopathy increases [4]. According to Yau et al. [5], the global prevalence of diabetic macular oedema is 7.4%. However, available data indicate that there is a higher prevalence of diabetic macular oedema in Africa which ranges from 5.7% - 33.3% compared to the 3.8% - 11% in Western countries [6-15]. The projections are that about 23.9 million African adults will live with diabetes by the year 2030, a 98% increase from 12.1 million [16]. The weak health care system in most African countries coupled with the epidemic rise of diabetes and its complications require urgent public health attention to improve quality of life among the aging population on the continent. It is also worth noting that the disease among Africans differ in terms of its clinical characteristics from Caucasians as there are reported late onset, 'atypical African diabetes', and malnutrition-related diabetes among the African cohort [15,17].

Although the pathogenesis of diabetic macular oedema is not fully understood, it is believed that it is mainly caused by the breakdown of the inner blood-retinal barrier [4]. Chronic hyperglycaemia causes an upregulation of vascular endothelial growth factor (VEGF) in diabetic retinopathy and diabetic macular oedema which then increases vascular permeability that further leads to increased angiogenesis [18,19,20]. As such, the current treatment regimen (use of anti-VEGFs) for diabetic macular oedema has mainly focused on direct inhibition of the activities of VEGF-A isoforms. These have supplanted initially used treatment protocols like focal/grid laser photocoagulation and become the first-line treatment for diabetic macular oedema, especially those involving the central fovea [21].

Notably, intravitreal injection of anti-VEGF drugs such as bevacizumab (Avastin, Genentech), ranibizumab (Lucentis, Genentech), aflibercept (Eylea, Regeneron Pharmaceuticals) have well been reported to improve visual acuity and reduce treatment complications in patients with diabetic macular oedema compared to other forms of treatment [22-27]. However, because bevacizumab is comparatively less expensive and widely available than the other drugs [21], they are commonly used in regions where supply and affordability of these drugs by patients are challenging. Bevacizumab, a recombinant humanized monoclonal immunoglobulin G1 antibody, is primarily designed to directly bind to VEGF extracellularly to prevent interaction with VEGF receptors on the surface of endothelial cells, which in turn inhibit VEGF's angiogenic activity [28,29]. This makes them very effective in preventing activities of VEGFs which are detrimental to the vision of patients with diabetic retinopathy.

Despite the significance and effectiveness of the various treatment regimen available for diabetic macular oedema, the effect of bevacizumab on diabetic macular oedema is still under-explored, especially in African populations even though marked differences exist in diabetes phenotypes of Africans and Caucasians. Thus, this study seeks to investigate the short-term effect of intravitreal bevacizumab's use for treating diabetic macular oedema in a Ghanaian population.

Materials and methods

The study was a retrospective cross-sectional study which involved assessment of case records of patients with clinical diagnosis of diabetic macular oedema who had undergone treatment with a single dose/injection of intravitreal bevacizumab (1.25 mg in 0.05 ml) at a private referral eye centre in Ghana. Clinical records of patients were first collected by two of the investigators JKA and EOO at different time points to ensure appropriate sampling of cases for the study. On agreement of the case folders to be included in the study (39 eyes of thirty-nine patients), demographic data and pre- and post-treatment clinical parameters (Snellen visual acuity converted to LogMAR [30] and macular thickness) of all selected patients were then recorded. All patients were diagnosed and treated by the same ophthalmologist who is experienced in the management of diabetic retinopathy and its associated complications. Patients who were diagnosed of diabetic macular oedema using Optical Coherence Tomograph imaging RTVue system Version #A6, 8,0, 27 (Optovue, Inc., Fremont, CA, USA) and treated between January 2014 and July 2019 were included in the study. All diagnosis were from scan area of the macula divided into nine Early Treatment Diabetic Retinopathy Study (ETDRS)-type regions, including a central disc of 500- μ m diameter (foveal region), and an inner and outer ring, each divided into four quadrants, with outer radii of 1 and 2 disc diameters, respectively (Fig 1C). The retinal thickness is reported for each of the ETDRS nine regions. The mean \pm standard deviation (SD) central foveal thickness was documented for six A-scans at the intersection of all the tomograms in the central macula. However, those with any prior treatment for the diabetic macular oedema, those whose fundus assessment was impossible due to media opacities, those with other retinal conditions including glaucoma, age-related macular degeneration, and those on any form of glaucoma treatment were excluded from the study. Ethical approval was obtained from the Institutional Review Board (IRB) of the University of Cape Coast, Ghana (UCCIRB/CHAS/ 2019/192) while written consent was obtained from the head of the eye care facility where the study was conducted before case folders were assessed. To ensure

anonymity and confidentiality, each folder was given a unique identification number and no patients' names were recorded. All information assessed were kept strictly confidential in line with the IRB's policies and the study protocol adhered to the tenets of the Declaration of Helsinki.

Statistical analysis was performed with STATA 16.1 (StataCorp, College Station, TX, USA) and a p-value of less than 0.05 was used to determine statistical significance. Paired t-test was used to ascertain the mean difference in visual acuity and central macular thickness before and after treatment while ordinary least squares linear regression was used to determine relationship between improvement in visual acuity and central macular thickness after treatment as well as how other variables predicted improvement in outcome measures (visual acuity and macular thickness after treatment). Mean, standard deviations, and 95% confidence interval were estimated for quantitative variables. Shapiro-Wilk test was conducted to assess normality of the data. Data were then presented in the form of tables and figures.

Results

Characteristics of patients

A total of thirty-nine patients who received a single dose of intravitreal bevacizumab injection for diabetic macular oedema in one of their two eyes were included in the study. Of this number, 51.3% were males. The mean age \pm (SD) of all patients was $61.4 \pm (15.0)$ years and ranged from 20 to 92 years. While majority (30.8%) of the patients were within the 51- to 60-year age group, only 10.3% were 20-40 years old. Table 1 summarises the characteristics of patients included in the study.

Table 1: Characteristics of patients

Characteristics	Frequency (%)	
	n = 39	
Sex	Male	20 (51.3)
	Female	19 (48.7)
Age	20-30	1 (2.6)
	31-40	3 (7.7)
	41-50	4 (10.3)
	51-60	12 (30.8)
	61-70	9 (23.1)
	71-80	5 (12.8)
	80+	5 (12.8)
Occupation	Civil servants	10 (25.6)
	Retirees	11 (28.2)
	Self-employed	11 (28.2)
	Unemployed	8 (12.7)
Eye treated	Right Eye	23 (59.0)
	Left Eye	16 (41.0)

Visual acuity before and after treatment with intravitreal bevacizumab

The mean visual acuity \pm SD of patients with diabetic macular oedema was 0.84 ± 0.58 LogMAR (range: 0.20-2.40 LogMAR) before treatment and improved to 0.69 ± 0.58 LogMAR (range: 0.00-2.40 LogMAR) six weeks after intravitreal bevacizumab injection (Table 2). A paired t-test showed that there was a statistically significant effect of intravitreal bevacizumab injection on patients' visual acuity after treatment (mean difference: 0.15 ± 0.32 LogMAR; 95% CI: 0.04 to 0.25; $p = 0.01$). Cohen's d test for effect size further indicated that there was an improvement in patient's visual acuity after treatment with intravitreal bevacizumab injection compared to visual acuity before treatment ($d = 0.47$). The proportion of patients that had better visual acuity after treatment compared to pre-treatment acuity was 43.6% ($n = 17$) while the proportion that had visual acuity worse than that before treatment was 12.8% ($n = 5$).

Central macular thickness before and after treatment with intravitreal bevacizumab

The mean central macular thickness \pm SD of patients with diabetic macular oedema was found to be 316.54 ± 75.35 μm (range: 169-479 μm) before treatment and reduced to 275.54 ± 57.43 μm (range: 158-447 μm) six weeks post-treatment with intravitreal bevacizumab (Table 2). A paired t-test revealed that there was a statistically significant improvement in patients' central macular thickness after treatment with intravitreal bevacizumab injection (mean difference: 41.00 ± 65.91 μm ; 95% CI: 19.64 to 62.36; $p < 0.001$). Cohen's d test for effect size further indicated that there was an improvement in patient's central macular thickness after treatment with intravitreal bevacizumab compared to macular thickness before treatment ($d = 0.62$). The proportion of patients that had a reduction in central macular thickness after treatment with intravitreal bevacizumab injection was 77% ($n = 30$) while a fifth had an increase in macular thickness post-treatment compared to pre-treatment with only one eye having similar macular thickness pre- and post-intravitreal injection.

Table 2: Visual acuity (LogMAR-equivalent of Snellen) and central macular thickness (μm) before and six weeks after treatment

Variables	Pre-treatment	6 weeks post-treatment	Mean difference \pm SD	p-value
Visual acuity				
Mean \pm SD	0.84 \pm 0.58	0.69 \pm 0.58	0.15 \pm 0.32	0.01 ^a
Median [IQR]	0.60 [0.5-1.0]	0.50 [0.2-1.0]		0.01 ^b
Central macular thickness				
Mean \pm SD	316.54 \pm 75.35	275.54 \pm 57.43	41.00 \pm 65.91	< 0.001 ^a
Median [IQR]	301 [258-361]	262 [236-312]		< 0.001 ^b

SD: Standard deviation, IQR: Interquartile range, ^a: p-value from paired t-test, ^b: p-value from Wilcoxon signed rank test

Prediction of improvement in visual acuity after treatment with intravitreal bevacizumab

A multiple linear regression analysis conducted revealed that there was a statistically significant linear relationship between visual acuity after intravitreal bevacizumab injection and pre-treatment visual acuity as well as age of patients after adjusting for all other predictor variables [F (4,34) = 33.84, $p < 0.001$, $R^2 = 0.76$). While pre-treatment visual acuity was a strong predictor of an improvement in visual acuity after treatment with intravitreal injection ($\beta_1 = 0.75$, 95% CI: 0.56 to 0.94; $p < 0.001$), age only mildly predicted improvement in visual acuity after treatment ($\beta_1 = 0.01$, 95% CI: 0.00 to 0.02; $p = 0.02$) after adjusting for pre-treatment macular thickness and sex of patients (Table 3). That is, for each LogMAR change in pre-treatment visual acuity, visual acuity after treatment with intravitreal bevacizumab changes by 0.75 LogMAR after adjusting for pre-treatment macular thickness and sex of patients ($\beta_1 = 0.75$).

Table 3: Improvement in visual acuity after treatment as predicted by other variables

Variables	Adjusted coefficient (β_1)	t-value	95% confidence interval	p-value
Pre-treatment visual acuity	0.75	8.09	0.56 – 0.94	< 0.001
Pre-treatment macular thickness	0.001	0.15	-0.00 – 0.01	0.89
Age	0.01	2.55	0.00 – 0.02	0.02
Sex	-0.18	-1.95	-0.34 – 0.01	0.06

Prediction of improvement in central macular thickness after treatment with intravitreal bevacizumab

A multiple linear regression analysis to assess improvement in macular thickness after treatment revealed that there was a statistically significant linear relationship between central macular thickness after intravitreal bevacizumab injection and pre-treatment macular thickness after adjusting for all other predictor variables [$F(4,34) = 4.79$, $p = 0.004$, $R^2 = 0.26$). That is, having adjusted for pre-treatment visual acuity, sex and age of patients, macular thickness at before treatment strongly predicted the chances of improvement in central macular thickness after treatment with intravitreal injection ($\beta_1 = 0.41$, 95% CI: 0.18 to 0.65; $p = 0.001$) (Table 4).

Table 4: Improvement in macular thickness after treatment as predicted by other variables

Variables	Adjusted coefficient (β_1)	t-value	95% confidence interval	p-value
Pre-treatment visual acuity	-4.81	-0.29	-38.18 – 28.56	0.77
Pre-treatment macular thickness	0.41	3.62	0.18 – 0.65	0.001
Age	-0.93	-1.54	-2.15 – 0.30	0.13
Sex	2.35	0.15	-29.95 – 34.64	0.88

Relationship between improvement in visual acuity and improvement in central macular thickness

Ordinary least squares linear regression analysis was conducted to assess the level of relationship between improvement in visual acuity (visual acuity before treatment – visual acuity after treatment) and improvement in central macular thickness (macular thickness before treatment – macular thickness after treatment). This revealed that there was only a weak positive linear relationship between the two parameters which was not statistically significant [F(1,37) = 2.59, p = 0.12, R² = 0.04]. Figure 1 illustrates the relationship between the two measures.

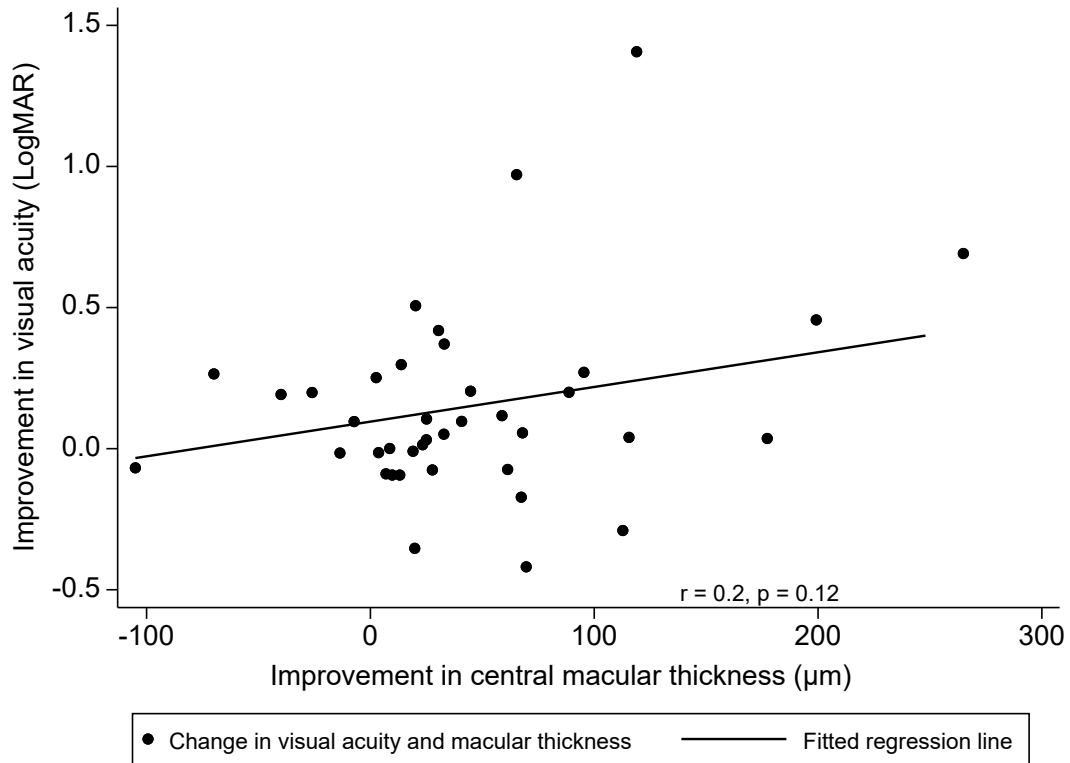


Fig 1: Relationship between improvement in visual acuity and improvement in central macular thickness

Improvement in patients' visual acuity as a predictor of improvement of macular thickness six weeks after treatment with intravitreal bevacizumab. Positive values of visual acuity represent improvement in visual acuity (better visual acuity) and vice versa while positive values of macular thickness represent improvement in central macular thickness (reduction in macular thickness) and vice versa.

Discussion

The results from this retrospective cross-sectional study which examined the effect of a single dose of intravitreal bevacizumab injection on visual outcomes in patients with diabetic macular oedema revealed that in the short term, bevacizumab is effective in improving visual acuity and reducing macular thickness. This was consistent with results from studies by Vyas et al. [31] Özkiriş [32], Lam et al. [33] and Seo and Park [34].

Visual acuity assessment at six weeks after a single dose of intravitreal bevacizumab injection in this study revealed that on average, patients' visual acuity (LogMAR-equivalent of Snellen) significantly improved by nearly two LogMAR lines. This was similar to that reported by Seo and Park [34] at four weeks following intravitreal injection but higher than that reported in a study by Roh, Byeon and Kwon [35]. On macular thickness, this study found that central macular thickness was markedly reduced which is consistent with majority of studies [31, 32, 33,34,35] conducted on the effect of bevacizumab on diabetic macular oedema which also reported a significant decrease in patients' macular thickness, despite the varying degree of reduction in each study. This highlights the effectiveness of the drug on reduction of macular thickness resulting from diabetic macular oedema, thus, complementing its use as first-line treatment for diabetic macular oedema.

Importantly, reports from studies which have investigated the effect of bevacizumab on visual outcomes in shorter time points (1-4 weeks) after injection still remain equivocal. For instance, in a study by Nagasawa et al. [36], it was reported that there was no significant improvement in mean best corrected visual acuity at one week after bevacizumab injection but a reduction in mean retinal thickness occurred at one week after injection. However, when this was assessed at four weeks, it was observed there was recurrence. Haritoglou et al. [29], on the other hand, reported an improvement in both visual acuity and macular thickness at two weeks post-injection. According to them, there was a significant improvement in mean visual acuity and a

substantial reduction in macular thickness in patients with diabetic macular oedema after they were treated with 1.25 mg of bevacizumab. Yet another study by Vyas et al. [31], has reported that visual acuity improved when assessment was conducted at first day post-bevacizumab treatment up to 6 weeks post-treatment. However, at eight weeks post-injection, visual acuity decreased which was attributed to increase in macular thickness [31]. This suggests the need for further studies to be conducted to investigate appropriate time points necessary for visual outcome assessment after intravitreal bevacizumab injection as that would produce accurate information which will guide treatment plan. Despite that, it would be worth pointing out that for shorter duration of assessment of visual outcomes following bevacizumab treatment, a six-week post-injection assessment may suffice as that is likely to produce enough evidence for prediction of prognosis.

Although not all eyes treated in this study had improvement in visual acuity, a significant proportion had an improvement, which was similar to that reported by Seo and Park [34] but fairly lower than that reported by Arevalo et al. [37]. This further shows that intravitreal bevacizumab is appropriate in producing an improvement in visual acuity, at least over a short period of time (six weeks). It was also observed from this study that pre-treatment visual acuity and macular thickness of participants predicted whether visual acuity and macular thickness would improve after treatment with intravitreal bevacizumab. This means, the lower the patients' visual acuity before treatment, the better it is after treatment. Likewise, the higher the patients' macular thickness, the higher the chances of it reducing after treatment. These findings aligned with results from a study by Kabunga et al. [38]. However, patients' improvement in visual acuity after treatment did not predict an improvement in their macular thickness. This indicates that intravitreal bevacizumab could produce a reduction in macular thickness but not an improvement in visual acuity in the same patient and vice versa. Thus, these two visual outcome variables should be treated independently.

Given that all patients included in this study were diagnosed of diabetic macular oedema by the same clinician, had had no prior treatment for the condition and had the primary cause of their macular oedema to be diabetic retinopathy alleviate the possibility of any confounders which would have potentially masked the true effect of the bevacizumab injection. However, the study was limited by the fact that visual outcomes were assessed at a shorter duration which essentially prevented evaluation of any long-term therapeutic efficacy of intravitreal bevacizumab. Follow up on patients over longer duration to assess possible rebound effect after treatment was also not possible due to the retrospective nature of the study. Even so, this protocol has been used by several researchers who have provided sufficient data to that effect. Given the lack of enough data on the use of intravitreal bevacizumab in an African population, it will be ideal for further studies to be conducted on the long-term efficacy of the drug possibly, at different time points of assessment as well as the effect of multiple doses of intravitreal bevacizumab in comparison to a single dose on treatment of diabetic macular oedema.

Conclusion

A single dose of intravitreal bevacizumab injection produces short-term improvement in vision and central macular thickness in patients with diabetic macular oedema in an African population. This could serve as first-line medical therapy for the management of diabetic macular oedema in resource-poor setting due to efficacy and relative affordability. Eye care practitioners should note that poor pre-treatment visual acuity and higher macular thickness before treatment are important predictors of improvement in visual acuity and reduction in central macular thickness respectively when assessed six weeks after treatment with intravitreal bevacizumab. However, improvement in patients' visual acuity does not necessarily suggest an improvement in central macular thickness as they are independent of each other.

Authors' contributions

SK conceptualized the project. SK and EZ designed the research project. JKA, FA and EOO carried out data collection. FAA analysed and interpreted the data. FAA, FA and SK wrote the original draft. SK, FAA, JKA, EZ, FA and KA wrote the reviews and edited the manuscript. All authors read and approved the final manuscript.

Consent for publication

Not applicable

Availability of data and materials

The datasets used and/or analysed during the current study are available from the corresponding author on reasonable request.

References

1. Mitchell P, Annemans L, Gallagher M, et al (2012) Cost-effectiveness of ranibizumab in treatment of diabetic macular oedema (DME) causing visual impairment: evidence from the RESTORE trial. *Br J Ophthalmol* 96(5):688–693
2. Cheung N, Mitchell P, Wong TY (2010) Diabetic retinopathy. *Lancet* 376(9735):124–136
3. Zhang X, Saaddine JB, Chou CF, et al (2010) Prevalence of diabetic retinopathy in the United States, 2005-2008. *JAMA Ophthalmol* 304(6):649–656
4. Massin P, Paques M, Pournaras, JA (2010) In: Levin LA, Albert DM. Ocular Disease: Mechanisms and management, China, Elsevier Inc Ltd, pp519-526
5. Yau JWY, Rogers SL, Kawasaki R, et al (2012) Global prevalence and major risk factors of diabetic retinopathy. *Diabetes Care* 35(3):556–564
6. Varma R, Bressler NM, Doan QV, et al (2014) Prevalence of and Risk Factors for Diabetic Macular Edema in the United States. *JAMA Ophthalmol* 132(11):1334–1340
7. Klein R, Knudtson MD, Lee KE, et al (2008) The Wisconsin Epidemiologic Study of Diabetic Retinopathy XXII: The Twenty-Five-Year Progression of Retinopathy in Persons with Type 1 Diabetes. *Ophthalmol* 115(11):1859–1868
8. Xie J, Ikram MK, Cotch MF, et al (2017) Association of Diabetic Macular Edema and Proliferative Diabetic Retinopathy With Cardiovascular Disease: A Systematic Review and Meta-analysis. *JAMA Ophthalmol* 135(6):586
9. Minassian DC, Owens DR, Reidy A (2012) Prevalence of diabetic macular oedema and related health and social care resource use in England. *Br J Ophthalmol* 96(3):345–349
10. Jivraj I, Ng M, Rudnisky CJ, et al (2011) Prevalence and Severity of Diabetic Retinopathy in Northwest Cameroon as Identified by Teleophthalmology. *Telemed e-Health*

17(4):294–298

11. Sukha AY, Rubin A (2009) Demographic, medical and visual aspects of Diabetic Retinopathy (DR) and Diabetic Macular Edema (DME) in South African diabetic patients. *Afr Vis Eye Heal* 68(2):70–81
12. Webb EM, Rheeder P, Roux P (2016) Screening in Primary Care for Diabetic Retinopathy, Maculopathy and Visual Loss in South Africa. *Ophthalmologica* 235(3):141–149
13. Mathenge W, Bastawrous A, Peto T, et al (2014) Prevalence and Correlates of Diabetic Retinopathy in a Population-based Survey of Older People in Nakuru, Kenya. *Ophthalmic Epidemiol* 21(3):169–177
14. Tsegaw A, Alemu S, Dessie A, et al (2021) Diabetic retinopathy in type 2 diabetes mellitus patients attending the diabetic clinic of the university of gondar hospital, northwest Ethiopia. *J Ophthalmol* 6696548. doi: 10.1155/2021/6696548.
15. Mbanya JCN, Motala AA, Sobngwi E, et al (2010) Diabetes in sub-Saharan Africa. *Lancet* 375(9733):2254–2266
16. IDF. Diabetes Atlas, 2021. https://diabetesatlas.org/atlas/tenth-edition/?dlmodal=active&dlsrc=https%3A%2F%2Fdiabetesatlas.org%2Fidfawp%2Fresource-files%2F2021%2F07%2FIDF_Atlas_10th_Edition_2021.pdf
17. Gill GV, Mbanya JC, Ramaiya KL, et al (2009) A sub-Saharan African perspective of diabetes. *Diabetologia* 52(1):8–16
18. Boyer DS, Hopkins JJ, Sorof J, et al (2013) Anti-vascular endothelial growth factor therapy for diabetic macular edema. *Ther Adv Endocrinol Metab* 4(6):151

19. Treins C, Giorgetti-Peraldi S, Murdaca J, et al (2001) Regulation of Vascular Endothelial Growth Factor Expression by Advanced Glycation End Products. *J Biol Chem* 276(47):43836–43841
20. Ascaso FJ, Huerva V, Grzybowski A (2014) The Role of Inflammation in the Pathogenesis of Macular Edema Secondary to Retinal Vascular Diseases. *Mediators Inflamm* 432685. doi: 10.1155/2014/432685
21. Wells JA, Glassman AR, Ayala AR, et al (2015) Aflibercept, bevacizumab, or ranibizumab for diabetic macular edema. *N Engl J Med* 372(13):1193–1203
22. Mitchell P, Bandello F, Schmidt-Erfurth U, et al (2011) The RESTORE study: Ranibizumab monotherapy or combined with laser versus laser monotherapy for diabetic macular edema. *Ophthalmol* 118(4):615–625
23. Elman MJ, Qin H, Aiello LP, et al (2012) Intravitreal Ranibizumab for Diabetic Macular Edema with Prompt vs Deferred Laser Treatment: 3-year Randomized Trial Results. *Ophthalmol* 119(11):2312
24. Do DV, Nguyen QD, Boyer D, et al (2012) One-Year Outcomes of the DA VINCI Study of VEGF Trap-Eye in Eyes with Diabetic Macular Edema. *Ophthalmol* 119(8):1658–1665
25. Ishibashi T, Li X, Koh A, et al (2015) The REVEAL Study: Ranibizumab Monotherapy or Combined with Laser versus Laser Monotherapy in Asian Patients with Diabetic Macular Edema. *Ophthalmol* 122(7):1402–1415
26. Elman MJ, Ayala A, Bressler NM, et al (2015) Intravitreal Ranibizumab for Diabetic Macular Edema with Prompt versus Deferred Laser Treatment: 5-Year Randomized Trial Results. *Ophthalmol* 122(2):375–381
27. Schmidt-Erfurth U, Lang GE, Holz FG, et al (2014) Three-year outcomes of individualized

- ranibizumab treatment in patients with diabetic macular edema: The RESTORE extension study. *Ophthalmol* 121(5):1045–1053
28. Jorge R, Costa RA, Calucci D, et al (2006) Intravitreal bevacizumab (Avastin) for persistent new vessels in diabetic retinopathy (Ibepe study). *Retina* 26(9):1006–1013
 29. Haritoglou C, Kook D, Neubauer A, et al (2006) Intravitreal bevacizumab (Avastin) therapy for persistent diffuse diabetic macular edema. *Retina* 26(9):999–1005
 30. Moussa G, Bassilious K, Mathews N (2021) A novel excel sheet conversion tool from Snellen fraction to LogMAR including 'counting fingers', 'hand movement', 'light perception' and 'no light perception' and focused review of literature of low visual acuity reference values. *Acta Ophthalmol* 99(6):e963–5
 31. Vyas S, Thapa R, Bajimaya S, et al (2016) Anatomical and visual outcome of intravitreal bevacizumab (Avastin) in patients with diabetic macular edema. *Nepal J Ophthalmol* 8(15):54–61
 32. Özkiriş A (2009) Intravitreal bevacizumab (Avastin) for primary treatment of diabetic macular oedema. *Eye* 23(3):616–620
 33. Lam DSC, Lai TYY, Lee VYW, et al (2009) Efficacy of 1.25 mg versus 2.5 mg intravitreal bevacizumab for diabetic macular edema: Six-month results of a randomized controlled trial. *Retina* 29(3):292–299
 34. Seo JW, Park IW (2009) Intravitreal Bevacizumab for Treatment of Diabetic Macular Edema. *Korean J Ophthalmol* 23(1):17–22
 35. Roh MI, Byeon SH, Kwon OW (2008) Repeated intravitreal injection of bevacizumab for clinically significant diabetic macular edema. *Retina* 28(9):1314–1318

36. Nagasawa T, Naito T, Matsushita S, et al (2009) Efficacy of intravitreal bevacizumab (Avastin™) for short-term treatment of diabetic macular edema. *J Med Investig* 56(3,4):111–115
37. Arevalo JF, Fromow-Guerra J, Quiroz-Mercado H, et al (2007) Primary Intravitreal Bevacizumab (Avastin) for Diabetic Macular Edema: Results from the Pan-American Collaborative Retina Study Group at 6-Month Follow-up. *Ophthalmol A*;114(4):743–50
38. Kabunga RR, Onyango J, Ruvuma S, Arunga S (2022) Outcome of intravitreal Avastin® injections in patients with macular oedema in Uganda: a cohort study. *Eye* 36(Suppl 1):45-50