



Rapidly non-ipf progressive fibrosing interstitial lung disease

Khine, N., Mudawi, D., Rivera-Ortega, P., Leonard, C., Chaudhuri, N., & Margaritopoulos, G. A. (2020). Rapidly non-ipf progressive fibrosing interstitial lung disease: a phenotype with an ipf-like behavior. *Sarcoidosis, vasculitis, and diffuse lung diseases : official journal of WASOG*, 37(2), 231-233.
<https://doi.org/10.36141/svdld.v37i2.9276>

[Link to publication record in Ulster University Research Portal](#)

Published in:

Sarcoidosis, vasculitis, and diffuse lung diseases : official journal of WASOG

Publication Status:

Published (in print/issue): 30/06/2020

DOI:

[10.36141/svdld.v37i2.9276](https://doi.org/10.36141/svdld.v37i2.9276)

Document Version

Publisher's PDF, also known as Version of record

Document Licence:

CC BY-NC

General rights

The copyright and moral rights to the output are retained by the output author(s), unless otherwise stated by the document licence.

Unless otherwise stated, users are permitted to download a copy of the output for personal study or non-commercial research and are permitted to freely distribute the URL of the output. They are not permitted to alter, reproduce, distribute or make any commercial use of the output without obtaining the permission of the author(s).

If the document is licenced under Creative Commons, the rights of users of the documents can be found at <https://creativecommons.org/share-your-work/ccllicenses/>.

Take down policy

The Research Portal is Ulster University's institutional repository that provides access to Ulster's research outputs. Every effort has been made to ensure that content in the Research Portal does not infringe any person's rights, or applicable UK laws. If you discover content in the Research Portal that you believe breaches copyright or violates any law, please contact pure-support@ulster.ac.uk

RAPIDLY NON-IPF PROGRESSIVE FIBROSING INTERSTITIAL LUNG DISEASE: A PHENOTYPE WITH AN IPF-LIKE BEHAVIOR

*Ngu Khine¹, Dalia Mudawi¹, Pilar Rivera-Ortega¹, Colm Leonard¹, Nazia Chaudhuri^{1,2},
George A. Margaritopoulos^{1,2}*

¹ILD Unit, Manchester University Hospital NHS FT, Southmoore Road, Manchester M23 9LT, UK; ²Faculty of Biology, Medicine and Health, The University of Manchester, Manchester M13 9PL, UK

ABSTRACT. *Background:* A subgroup of patients with fibrotic ILD experience progression and several risk factors for ILD progression have been reported, such as male sex, older age, lower baseline pulmonary function, and a radiological or pathological pattern of usual interstitial pneumonia. *Objective:* To describe a possible new phenotype of rapidly non IPF progressive fibrosing with an IPF-like outcome. *Methods:* Three previously fit and well patients who developed a rapidly progressive ILD and died within 6 to 7 months from the initial development of respiratory symptoms. *Results:* Unlike what is currently known, our patients developed a severe fibrosing ILD with an IPF-like outcome despite a) being younger than the average patient with IPF, b) having received a non-IPF MDT diagnosis, c) having a non-UIP pattern on HRCT. Moreover and similarly to IPF, they failed to respond to immunosuppressive treatment which is the preferred treatment option in these cases. *Conclusion:* We believe that patients who present with similar characteristics should be considered as likely to develop a phenotype of rapidly progressive ILD and be treated with antifibrotic medications instead of immunosuppressive ones according to the favourable treatment response to antifibrotic therapy observed in clinical trials of patients with progressive fibrosing ILDs. (*Sarcoidosis Vasc Diffuse Lung Dis* 2020; 37 (2): 231-233)

KEY WORDS: Progressive, Fibrosis, IPF, ILD, UIP, NSIP

Progressive fibrosis is a characteristic of several interstitial lung diseases (ILD) that is strongly linked with mortality. Idiopathic pulmonary fibrosis (IPF) represents the prototype of inexorably progressive ILD [1]. Other fibrosing ILDs (idiopathic nonspecific interstitial pneumonia (NSIP), chronic fibrosing hypersensitivity pneumonitis, connective tissue disease (CTD)-associated ILD and unclassifiable fibrotic ILD) characterized histologically by a combination of inflammation and fibrosis can

have an IPF-like behavior [2]. It was suggested that these subgroups of individual ILDs are amalgamated under the term of “progressive fibrosing ILDs” (PF-ILDs) [2]. However, there are unanswered questions regarding the a) diagnostic criteria [3], b) predictors of outcome [2] and c) appropriate treatment [4].

We present three cases of PF-ILD with striking clinical and possibly pathogenetic similarities (patients in their forties, ex/current smokers, unremarkable medical history, fully active prior to the development of respiratory symptoms which was triggered by respiratory infections, multidisciplinary diagnosis of rapidly non-IPF PF-ILD with IPF-like outcome). We believe that these cases may represent a specific phenotype of “rapidly” PF-ILD.

Case 1: A 49-years-old male, current smoker (pack-year:15) who worked in a warehouse presented

Received: 11 February 2020

Accepted after revision: 20 May 2020

Correspondence: George A. Margaritopoulos MD, PhD
ILD Unit, Manchester University Hospital NHS FT,
Wythenshawe Hospital, Southmoor Road,
Wythenshawe, Manchester M23 9LT, UK
georgios.margaritopoulos@mft.nhs.uk, gmargaritop@yahoo.gr

with a 3 months history of rapidly progressive breathlessness and cough triggered by a chest infection. At presentation, he used supplemental oxygen (3litres/minute at rest, 10litres/minute on ambulation). We identified possible occupational exposures. There was no evidence of CTD. The autoimmune screen was negative. The FEV₁ was 1.85 liters (55%), the FVC was 1.91 (46%), and the total lung capacity was 42%. A computed tomography (CT) pulmonary angiogram excluded pulmonary embolism and a high resolution (HR) CT showed a severe fibrotic ILD (NSIP pattern) with emphysema (Figure 1a). The echocardiogram showed a pulmonary artery systolic pressure of 52mmHg and right ventricular systolic dysfunction. He received intravenous and subsequently low-dose oral corticosteroids. Six weeks later, he presented with an acute exacerbation (AE) of ILD. The HRCT showed further progression (Figure 1b). He received intravenous antibiotics (CRP:15, negative cultures) and high dose oral steroids without any effect. He died 5 months after the development of significant symptoms.

Case 2: A 42-year-old male ex-smoker of one year (pack-year:15), bank clerk, referred with a 10 weeks history of progressive breathlessness developed after a chest infection which did not improve after several courses of antibiotics. At presentation, his exercise tolerance was 50 yards on the flat. The oxygen saturation at rest varied between 88%-92%. The bronchoalveolar lavage showed neutrophilia (35%) without microbial growth. The autoimmune screen was negative. There was no evidence of CTD and environmental exposures. The FEV₁ was 1.58L (39%), FVC was 1.7L (35%), the DL_{CO} was 38%. The HRCT showed an overlap between NSIP/organizing pneumonia [Figure 2a]. The echocardiogram was normal. His mother was under investigation for pulmonary fibrosis and his CT scan also showed evidence of liver cirrhosis raising the possibility of familial ILD. Genetic tests were not performed. Ambulatory oxygen was prescribed. He received oral prednisolone and 4 weeks later HRCT (Figure 2b) and lung function [FVC:1.38 (28%)] showed further progression. He received intravenous corticosteroids. Four weeks later, he presented with an AEILD. He was treated with high dose of oral corticosteroid and antibiotics (CRP:20, negative cultures). He died six months after the development of symptoms.

Case 3: A 43-year-old gentleman, ex-smoker of one year (pack-years: 25), book author, developed extreme fatigue, progressive breathlessness and cough associated with recurrent chest infections. At presentation he used supplemental oxygen (2litres/min at rest, 4litres/min on ambulation). The autoimmune screen was negative. Except from fatigue and non-specific joint pains, there was no clinical evidence of CTD. There were no environmental exposures. The HRCT showed a pattern of fibrotic NSIP with emphysema (Figure 3a). The echocardiogram was unremarkable. The FEV₁ was 2.8 L (74.5%), the FVC was 3.27 (71%), the DL_{CO} was 35%. He received intravenous and subsequently oral corticosteroids. Six weeks later, he described increased breathlessness although the oxygen requirements and lung function were stable. Mycophenolate Mofetil was added. Four weeks later he presented with an infective AEILD (CRP:110), increased oxygen requirements and a significant HRCT deterioration (Figure 3b). He received intravenous antibiotics. However, the oxygen requirements were further increased and he received again intravenous corticosteroids without any effect. He died 3 days later, 7 months after the development of respiratory and systemic symptoms.

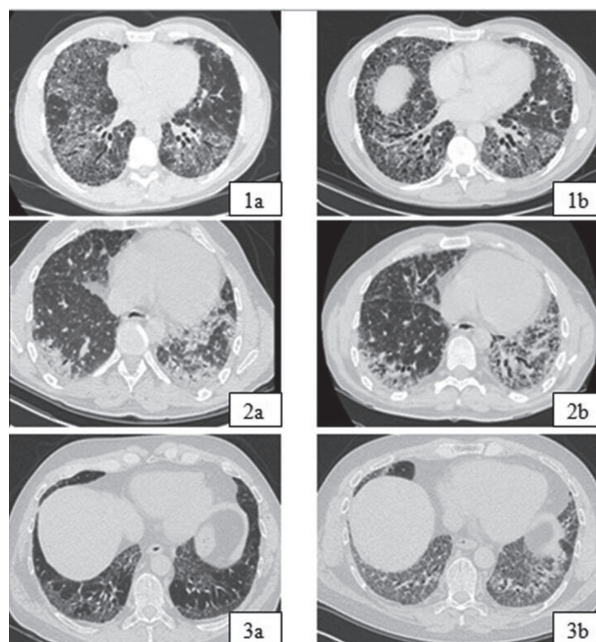


Fig. 1. HRCT at presentation (a) and at the time of AEILD (b).

Currently little is known about PF-ILD and most of the knowledge is extrapolated from studies on the prototype of PF-ILD, namely IPF. Our patients were younger than the average patient with IPF. We believe that, similarly to IPF clinical phenotypes [5], a phenotype of “rapid progressors” exists in non-IPF PF-ILDs. We observed that, unlike the majority of non-IPF PF-ILDs in which rapid progression is associated with the pattern of usual interstitial pneumonia (UIP) on HRCT [2], the “rapid progressor” phenotype can also present with a pattern of NSIP. Very few studies showed in the past that idiopathic NSIP can behave like IPF and our observation supports these findings [6-7]. We observed similarities between the non-IPF “rapid progressor” phenotype and IPF. Smoking, acute worsening of breathlessness, short-term disease progression and initiation of supplemental oxygen, common features in all three cases, predict mortality in IPF [8-11]. Our patients had a history of respiratory infections and it appears logical to hypothesize that immune defects and alteration of microbiome could be implicated in the pathogenesis and progression, similarly to IPF [12-13]. Another peculiarity is that the use of immunomodulation had a detrimental effect on survival. It is hoped that in non-IPF PF-ILDs the use of immunomodulation would stabilize or prevent progression given the hypothesis of fibrosis/inflammation co-existence [4]. We think that, despite the non-IPF diagnosis, immunomodulation may not be the ideal treatment in the context of PF-ILDs, in line with what was observed in IPF [14] and that antifibrotics may be a better choice given the results of recent trials [15-16].

We acknowledge that the absence of genetic tests represents a limitation of our study. It should be stressed however, that the performance of genetic tests has not been approved on a routine basis and most of the times funding is not available outside research projects. This is the reason for which, although a familial form has been suspected, genetic tests were not performed. We also acknowledge that the performance of bronchoalveolar lavage together with a transbronchial cryobiopsy would be significantly helpful for diagnostic and treatment purposes. However, the respiratory status of all patients both at presentation and during follow-up did not allow the performance of semi- or invasive procedures.

In summary, we present three cases of rapidly PF-ILDs which despite the absence of a definite/provisional diagnosis of IPF and of a UIP pattern on HRCT, had a typical IPF outcome. This is an almost unexplored field and large observational studies are warranted to better characterize the PF phenotype in terms of diagnosis and management.

REFERENCES

1. Travis WD, Costabel U, Hansell DM, et al. An official American Thoracic Society/European Respiratory Society statement: update of the international multidisciplinary classification of the idiopathic interstitial pneumonias. *Am J Respir Crit Care Med* 2013; 188: 733-748.
2. Wells AU, Brown KK, Flaherty KR, Kolb M, Thannickal VJ; IPF Consensus Working Group. What's in a name? That which we call IPF, by any other name would act the same. *Eur Respir J* 2018; 51: 1800692.
3. Cottin V. Treatment of progressive fibrosing interstitial lung diseases: a milestone in the management of interstitial lung diseases. *Eur Respir Rev*. 2019;28.
4. Collins BF, Raghu G. Antifibrotic therapy for fibrotic lung disease beyond idiopathic pulmonary fibrosis. *Eur Respir Rev* 2019; 28: 190021
5. King TE Jr, Pardo A, Selman M. Idiopathic pulmonary fibrosis. *Lancet*. 2011;378:1949-61.
6. Latsi PI, du Bois RM, Nicholson AG, et al. Fibrotic idiopathic interstitial pneumonia: the prognostic value of longitudinal functional trends. *Am J Respir Crit Care Med* 2003; 168: 531-537
7. Jegal Y, Kim DS, Shim TS, et al. Physiology is a stronger predictor of survival than pathology in fibrotic interstitial pneumonia. *Am J Respir Crit Care Med* 2005; 171: 639-644
8. Antoniou KM, Hansell DM, Rubens MB, et al. Idiopathic pulmonary fibrosis: outcome in relation to smoking status. *Am J Respir Crit Care Med*. 2008; 177:190-194
9. Margaritopoulos GA, Vasarmidi E, Jacob J, Wells AU, Antoniou KM. Smoking and interstitial lung diseases. *Eur Respir Rev*. 2015;24: 428-35.
10. Sharp C, Adamali HI, Millar AB. A comparison of published multidimensional indices to predict outcome in idiopathic pulmonary fibrosis. *ERJ Open Res* 2017; 3: 00096-2016.
11. Cottin V, Hansell DM, Sverzellati N, et al. Effect of emphysema extent on serial lung function in patients with idiopathic pulmonary fibrosis. *Am J Respir Crit Care Med* 2017; 196: 1162-1171.
12. Molyneaux PL, Cox MJ, Willis-Owen SA, et al. The role of bacteria in the pathogenesis and progression of idiopathic pulmonary fibrosis. *Am J Respir Crit Care Med* 2014; 190: 906-913.
13. Molyneaux PL, Cox MJ, Wells AU, et al. Changes in the respiratory microbiome during acute exacerbations of idiopathic pulmonary fibrosis. *Respir Res*. 2017;18:29.
14. Idiopathic Pulmonary Fibrosis Clinical Research Network, Raghu G, Anstrom KJ, King TE Jr, Lasky JA, Martinez FJ. Prednisone, azathioprine, and N-acetylcysteine for pulmonary fibrosis. *N Engl J Med*. 2012;24;366:1968-77.
15. Flaherty KR, Wells AU, Cottin V, et al. Nintedanib in Progressive Fibrosing Interstitial Lung Diseases. *N Engl J Med*. 2019;381: 1718-1727.
16. Maher TM, Corte TJ, Fischer A et al. Pirfenidone in patients with unclassifiable progressive fibrosing interstitial lung disease: a double-blind, randomised, placebo-controlled, phase 2 trial. *Lancet Respir Med*. 2020;8:147-157.